

4 mm cannulated cancellous screws fixation in extra articular distal 1/3 radius fracture - A study

M.S. Patil*, M.W. Khan and Faisal A. Mallick

Department of Orthopaedic, Al-Ameen Medical College and Hospital, Athani Road, Vijayapur-586108 Karnataka, India

Abstract: *Background:* Distal radius fracture are extremely common and represents 16% of fractures treated by orthopaedic surgeons. Near anatomical reduction with restoration of radial length, radial tilt and ulnar variances are important for good functional results. Cannulated 4 mm long threaded using minimally invasive osteosynthesis technique are less aggressive towards soft tissue covering. It allows immediate range of motion of the wrist while maintaining alignment resulting in rapid and comfortable functional recovery. The objective of this study was to evaluate the clinical, radiological and functional efficacy of 4 mm cannulated screws in the management of extra articular distal radius fracture using the criteria of Gartland and Werley point system. *Material & Method:* 40 Patients with extra articular distal radius fracture were treated by minimally invasive osteosynthesis technique using 4 mm cannulated cancellous screws in AL-Ameen Medical College Hospital, Bijapur between Nov 2013 to Oct 2015 which included 19 males and 21 female patients. The duration of follow-up was ranged from 12-18 months. *Results:* Using Demerit scoring system of Gartland and Werley, we had 45% excellent, 50% good, 0% fair and 5% poor results. As per our results, excellent to good results were found in 95% of patients. *Conclusion:* Cannulated cancellous screws fixation is an effective means of fixation in distal 1/3 radius fracture, allowing immediate range of motion of the wrist, resulting in a rapid and comfortable functional recovery while maintaining alignment and bone healing. It has higher degree of purchase when treating extra articular distal radius fracture with poor bone quality. Being minimally invasive with minimal soft tissue dissection, less operative time, cost effective, cannulated screws is a good option for both young and elderly patients with extra articular distal radius fracture.

Keywords: Distal radius, Extra articular fracture, Minimally invasive osteosynthesis, Cannulated cancellous screws, Radial length, Radial inclination

Introduction

Fracture of the distal radius is one the most common skeletal injuries treated by the Orthopaedic surgeons. These injuries account for approximately 16% of all fractures treated by Orthopaedic surgeons, since its first description by Pouteau 1783 and later Abraham colles in 1814 [1].

Needless to say, the medical world has changed since the days of the eponymous Colles and has so has the etiology, diagnosis, classification and the treatment of distal radius fracture [2]. The first era in the management of distal radius fracture describes manipulating a fractured arm until it is straight, then applying splints of wood and rolls of linen, which were subsequently hardened with grease and honey to maintain their position. Earliest roots fall to the ancient greeks [3]. In 1895 wilhelm Roentgen's discovery of X-

rays [4-5] marked a significant milestone in the evaluation of the degree of displacement and articular involvement and management of fractures.

Restoration of the radial length, radial tilt and ulnar variance are important for good functional results. Failure to achieve and maintain near anatomic reduction can lead to degenerative arthritis, radio-ulnar instability and ulnar impaction syndrome with resultant pain, decreased mobility, strength and function [6]. In seeking better clinical and functional results, surgical methods are increasingly indicated and there has been great evolution in the implants developed for the distal end of radius [7]. Physicians developed complex splints in a wide variety of wrist positions to attempt to prevent collapse [8-9]. The pivot work in antiseptics by Lister,

paved the way to make primary surgical fixation a safe enough and a prudent option in the management of fractures [10]. Lambotte in 1908, described the use of percutaneously placed wire through the radial styloid to maintain reduction, it took 40 years of case series with results using K-wire, until it was published in Literature. Closed reduction with percutaneous pin fixation has historically been the most common method for unstable extra articular distal radius fracture [11].

However, specific limitations and complications have decreased its popularity. Lack of rigidity, need for restrictive immobilization and skin irritation may limit the success of the postoperative rehabilitation period. Pin migration, Pin breakage, Pin tract infection, malunion and nerve injury are common complications [12]. Last decade saw the popularity of locking plate, which theoretically gave better stabilization [13].

Its threaded screws gave better purchase and hold on to the segment but the problem is soft tissue dissection, risk of surgery and implant not being cost effective. The most recent era has seen refinement of the available techniques and continuing research to better understand the appropriate indications for each interventions. Surgeons have brought innovations to the previously described procedure to improve results and manufacturers have succeeded in improving implant design and materials [14]. In 1944 Anderson and O'Neil developed a design in which pins were placed in the proximal radius and the index metacarpal distally and were kept at a length with a simple bar, giving the first design of the external fixator. Thus surgeons were able to predictably prevent what had previously been considered inevitable radial shortening. Vidal put forwarded the theory of ligamentotaxis [15].

Percutaneous pinning through closed reduction in different patterns was started. Various techniques of wire insertion through the fracture site and insertion across the fracture site, the former was described by Kapandji in 1976 and since then various modifications have been introduced. Kapandji revolutionized intrafocal pinning in which K wires are introduced through the fracture to trap the fragment and are driven into the proximal opposite intact cortex [16]. The Sauve-Kapandji procedure became the established treatment option for symptomatic distal radio

ulnar joint dysfunction. However for patients with poor bone quality, the conventional SK procedure is difficult to perform without reducing the radio ulnar diameter of the wrist. Which may result in a loss of grip strength and pain over the proximal ulna. Fixation using external fixators are an attractive alternative. The length of the radius is maintained, and the articular surface is reconstituted by "ligamento-taxis" without exposing the joint, the use of external fixation has not gained the popularity it might. Significant loss of reduction is attributable to pin loosening, infection and fixator failure, joint stiffness and nerve injury does not make it a first choice in modern Orthopaedic line of treatment [17].

The use of percutaneous pinning is accepted practice for the treatment of Distal radius fracture, but it gives marginal improvement in the radiological parameter compared with immobilization in cast alone and it does not correlate with an improved functional outcome. Loosening of pins and malunion became the major concern. Dissatisfaction with use of percutaneous pinning led to volar plating, achieving anatomical reduction, stable fixation to allow early range of motion and rehabilitation. But with longer duration of operation time and medical fitness plus significant soft tissue dissection and complication rate became a hindrance.

Minimally invasive osteosynthesis techniques and approaches towards soft tissue have become more biological [18]. There are different options available for the fixation of distal radius fractures. Cannulated cancellous screw technology is one of these options and is applicable to distal radius fractures [19]. The purpose of this study is to evaluate functional, clinical and radiological effectiveness and drawbacks after closed reduction percutaneous fixation of acute, displaced extra articular and unstable fracture of the distal radius by using a standard 4.0 mm diameter long threaded cannulated screw in Indian population. Percutaneous 4 mm cannulated cancellous screw, a new method of fracture fixation with 4 mm cannulated screw applied percutaneously after closed reduction. The screw gives good purchase to the bone

and fixes the fragments, it is more stable alternative to K wire which falls short when it comes to giving rotational stability. Early mobilization reduces the chance of joint stiffness. It is an inexpensive technique. Closed reduction and percutaneous application reduces the operative risk to the minimum level with 4 mm diameter it is possible to put two screws instead of one.

1. John STaras, Feb 25-28 2009, Las Vegas (American Academy of Orthopaedic Surgeons) did a study on stable distal radius fracture fixation possible with threaded pinning method. He said threaded pinning method is a more stable alternative to the smooth pins because of the two threaded variable length cannulated pins which act like screws to gain good purchase of the bone and fix the fragments.
2. Studies were done using 4 mm cannulated screws (NalbanToglu U GeretiakoConoglu B Turkman M) They concluded that cannulated screw fixation is an effective means of allowing immediate range of motion of wrist resulting in rapid comfortable functional recovery while maintaining alignment to bone healing
3. Comparative study of close reduction percutaneous screw fixation and open reduction with palmar locking plate fixation (MetinTurkmanTrelgereli). The confusion was that the CRPCF group was found to be as successful as ORPLP group and it may be suitable in the case of young active individuals [20].

Hypothesis being the fixation with cannulated screw would allow immediate range of motion of the wrist while maintaining alignment, resulting in a rapid and comfortable functional recovery [4].

Material and Methods

Study was conducted between Nov 2013 to Oct 2015 in AL-AMEEN Medical College & Hospital, Orthopaedic Department Bijapur. 40 cases of extra articular distal 1/3 radius fracture were selected, classified on Gartland & Werley system. Radiographs, anteroposterior & lateral were taken to exclude intra articular involvement. All patients selected for study were admitted, examined according to protocol,

associated injuries if any were noted, clinical and laboratory investigations were done, in order to get fitness for surgery. Closed reduction internal fixation with 4 mm cannulated cancellous screws were done and assesment at 2 months, 6 months, 12 months and final evaluation was performed at 18 months using Demerit-point system of Gartland and Werley.

Procedure: Surgery is performed at a mean 0.6 day's (range 0-6day's). Patient is placed supine on operating table with shoulder abducted 90 degree and the elbow flexed to approximately 70 degree. Once the patient is anaesthetized, longitudinal traction through hand holding thumb and fingers, counter traction holding at elbow is given by assistants. Closed reduction under fluoroscopic guidance is achieved on manipulation. Once the anatomic reduction is achieved, a guide wire placement is done through radial styloid from distal to proximal fragment, starting volar distally through fracture and ending dorsal proximally (ulnar side). Second guide wire is placed similarly from lateral side, starting through proximal fragment volar aspect through fracture site and ending in distal fragment dorsal (ulnar side). Incision of 1 cm length is made around the guide wires, taking care to avoid injury to tendons and cutaneous branch of radial nerve.

After the measurement for screw length, the near cortex is drilled with a sleeve to protect the soft tissue. A 4.0 mm cannulated cancellous long threaded screw is inserted over the guide wire under fluoroscopic guidance. Screws are placed close to the volar cortex, which is located in much more favourable biomechanical position, to increase the bone contact and support to the far cortex, thereby increasing stability. Screws are slightly buried into the bone to prevent tendon irritation. Clinical photographs of the technique on bone model is shown in fig 1 and 2. Post-operatively the limb is immobilized in short arm cast, which is removed on an average of 2 weeks and encouraged for range of motion with removable protecting splint. Heavy labour was permitted after 3 months of surgery. Pre and post operative x-rays are shown in Fig 3 and 4.

Fig-1: Technique showing screw fixation on cadaveric Bone - A.P. view

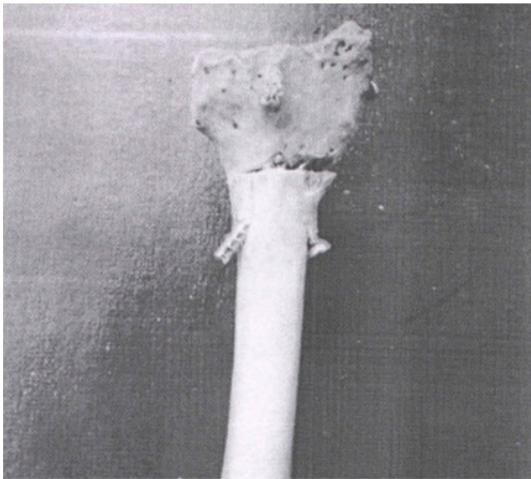


Fig-2: Technique on cadaveric Bone Model - Lateral View

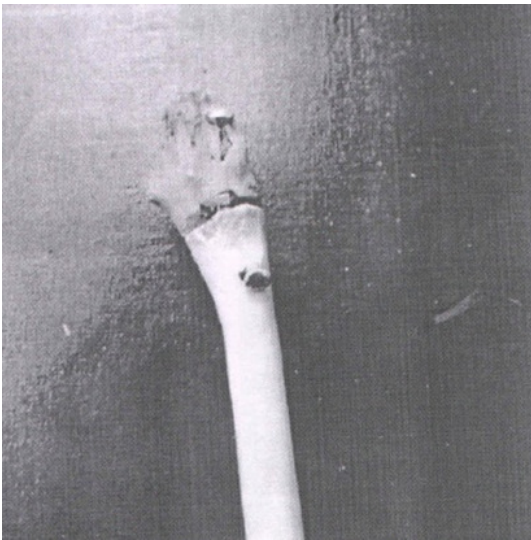


Fig-3: Preoperative X-ray

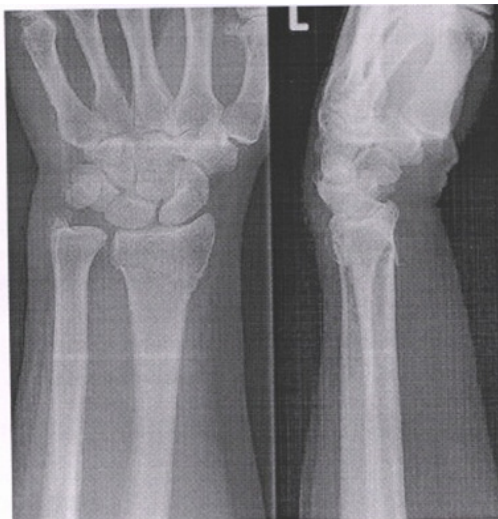
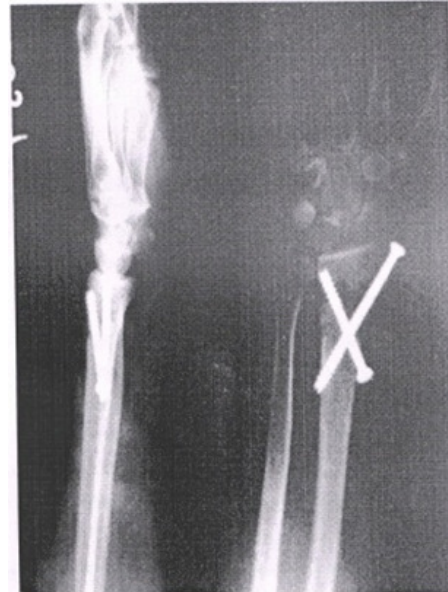
Fig-4: Post-Operative X-ray



Results

Out of 40 patients, enrolled for study. 21 were Female and 19 Male, 19 involving the left side and 21 right side, as shown in Table No 1. Patients were scheduled for a weekly visit in the first month and latter in 2nd, 6th, 12th and 18th month after surgical procedure for evaluation. The 18 month follow-up was scheduled to see mainly for any late complications. Objective measures included wrist flexion, extension, ulnar-radial deviations and forearm supination-pronation. Result distribution of patients in relation to gender, according to Gartland and Werley scoring system are shown in Table No 2. Radiographic assessment was made on the standard anteroposterior and lateral projection as described by radiological and anatomical scoring system. Values were compared statistically. Complications that occurred during the process were distributed on gender basis and shown in Table No 3.

Table-1: Showing side involved in various genders			
Side Involved	Gender		Total
	Female	Male	
Left	10(47.6%)	9(47.4%)	19(47.5%)
Right	11(52.4%)	10(52.6%)	21(52.5%)
Total	21(100%)	19(100%)	40(100%)

Table-2: Showing Result distribution in various genders

Gender	Results			Total
	Excellent	Good	Poor	
Female	7 (38.9%)	13 (65%)	1 (50%)	2 (52.5%)
Male	11 (61.1%)	7 (35%)	1 (50%)	19 (47.5%)
Total	18 (100%)	20 (100%)	2 (100%)	40 (100%)

Table-3: Showing complications in various genders

Complications	Gender		Total
	Female	Male	
Nil	16(76.2%)	15(78.9%)	31(77.5%)
Occasional Pain	4(19%)	3(15.8%)	7(17.5%)
Finger Stiffness	0(0%)	0(%)	0(0%)
Malunion	1(4.8%)	1(5.3%)	2(5.0%)
Total	21(100%)	19(100%)	40(100%)

Statistical Method: Descriptive and inferential statistical analysis has been carried out in the present study. Results on continuous measurements are presented on Mean ± SD (Min-Max) and results on categorical measurements are presented in number (%). Significance is assessed at 5% level of significance. The following assumptions on data is made.

Assumptions:

1. Dependent variables should be normally distributed
2. Samples drawn from the population should be random. Cases of the sample should be independent.

Chi-square/Fisher Exact test has been used to find the significance of study parameters on categorical scale between two or more groups.

Significant Figures

+ Suggestive Significance (P value: 0.05 < P < 0.10)

* Moderately Significant (P value: 0.01 < P ≤ 0.05)

** Strongly Significant (P value: P ≤ 0.01)

Statistical Software: The statistical software namely SAS 9.2, SPSS 15.0, Stata 10.1, MedCalc 9.0.1, Systat 12.0 and R environment ver.2.11.1

were used for the analysis of the data and Microsoft Word and Excel have been used to generate graphs, tables etc.

Discussion

Minimally invasive osteosynthesis has been growing worldwide. Patients who undergo minimally invasive procedure experience small incision scars, minimal blood loss, shorter hospital stay and quick rehabilitation. Advances in instrument and imaging technology have improved how orthopaedic surgeons treat different type of fractures, thus various conditions can now be managed with minimally invasive technique. To this end, cannulated screws have been used extensively and are well described in the upper extremity surgery and treatment of distal radial fractures. They are generally used for fixation or reinforcement of radial styloid fractures, but data on the treatment of completely displaced, extra articular metaphyseal fractures are limited. Evolution of treatment has taken place along two lines technically, through implant designing and biologically through stabilizing the bone, providing rigid fixation and preserving the covering of soft tissues, thus enabling comfortable post-operative period, while reducing the restrictive immobilization time and early functional recovery.

In our series, 40 patients were treated with closed reduction with 4 mm cannulated screws fixation with minimum follow up of 12 months. Analysed according to Demerit point system of Gartland and Werley. Casts were removed at 2 weeks and encouraged to do their daily activity (non-weight bearing) with a removable protecting splint. At 2 months most of patients had 60% improvement with our subjective evaluation, between 2 to 6 months majority of the patients had near to normal daily activity with improvement in both subjective and objective evaluation. These results indicate cannulated screw fixation appears to provide effective fixation. Allowing immediate range of motion in the early post-operative period and comfortable return to functional independence.

In our series of 40 patients, age distribution of the patients was 20-30 years 12 patients, 31-40 years 8 patients, 41-50 years 10 patients, 51-60 years 2 patients, 61-70 years 6 patients, more than 70 years 2 patients. The mean age being 42.83 years. In Ufuk Nalbantoglu, Arel Gereli series of 20 patients the mean age of patients were 39 years minimum being 18 years and maximum 60 years. Thus compared to this series, the number of patients in our series were more and the mean age was high with about 20% of the patients being above 60 years of age, reason being we wanted to evaluate the implant in a broader age group especially in elderly population. We observed that the 2 cases in which we had poor results, belonged to the above 60 yrs age group. The mechanism of injury in our series is fall from height 16(40%). Fall on out stretched hand 15(37.5%), road traffic accident 7(17.5%), direct injury 2(5%). In Ufuk Nalbantoglu, Arel Gereli series the mechanism of injury was fall from standing height in 16 cases, fall from height in 3 cases and sports related injury in 1 case. In our series results were analysed by Gartland and Werley scoring system. 18(45%) patients had excellent results, 20(50%) patients had good results, 2 (5%) patients had poor results.

In Ufuk Nalbantoglu, Arel Gereli series of 20 patients analysed by Gartland and Werley scoring system, with a follow up of 12 months, 15 results were rated as excellent and 5 results as good with no fair or poor results. The high number of excellent to good results in comparison to our results were may be due to, that they have not

included elderly population in their study as maximum age of their subject was 60 years and poor bone quality (osteoporotic bone) was excluded in their study group. Where as in our series we had 20% of the patients with age more than 60 years with osteoporotic bone. We included elderly patients as we wanted to evaluate strength of this implant in osteoporotic bone. We had complications in 4 cases out of 40 total cases. 2 patients had irritation in first dorsal compartment due to prominence of screw, which were removed at an average of 9 months. Both of them showed total improvement in their symptoms after removal. 2 patients had loss of reduction with pain in the wrist, which were kept in poor category.

We included elderly patients as our subject with poor bone quality as we wanted to see the purchase of the implant in osteoporotic bone and we got 75% of excellent to good results. This tells the efficacy of the implant even in elderly subjects. The study had some limitations. In this study only extra-articular fractures of distal radius were included and only local population was studied. Considering the lack of a clinical study regarding cannulated screws fixation in distal 1/3 radius fractures, we tried to show cannulated screws as useful option. We observe that a future comparative study with other implants is required to understand the efficacy of cannulated screws with other types of the implants for distal 1/3 radius fractures, to prove its supremacy over other implants in different parameters.

Conclusion

Cannulated cancellous screw is an effective means of treatment of distal radius fracture allowing immediate range of motion of the wrist, resulting in a rapid and comfortable functional recovery while maintaining alignment and bone healing. It has higher degree of purchase when treating extra-articular distal radius with poor bone quality. Being minimally invasive with minimal soft tissue dissection, less operative time, cost effective. Cannulated screws is a good option for both young and elderly patients with extra articular distal radius fracture.

Acknowledgement

We are indebted to our beloved Director, Dean, Head of Department and staff of Orthopaedic Department for

their comments and technical assistance with this article. We also thank all the Post-graduates and patients, who took part in this study.

References

1. Ebers Papyrus. The book of medical knowledge of 16th century BC, egyptinshallammikolajczak, *Archieve, History filooz med* 2004; 67(1):5-48.
2. Saffer P. Current trends in the treatment and classification of distal radius fractures. *Orthoclinic North America*.1995; 15:12-18.
3. Hippocrates, Democritus. Useful known and unknown views of the fracture of modern medicine. *Hellenic journal of nuclear medicine*. 2008; 11(1):2-4.
4. Usten C. Initiation of the adventure of x-rays in Turkey. *Eur J Radio* 2010; 75(3):343-345.
5. Eugene W Coldwell, Lecture. Past, Present and Future of x-rays. *The American Journal of Roentgenology*.1995; 164(6):1323-1328.
6. David L, Helfet MD, Norbert P. AO Philosophy and principles of Fracture Management, Its Evolution and Evaluation. *Journal of Bone and Joint Surgery*. 2003; 85(6):1156-1160.
7. Simic PM, Wieland AJ. Fractures of the distal aspect of the radius, Changes in treatment over the past two decades. *J Bone Joint Surg (Am)*. 2003; 85-A: 552-564.
8. Sarmiento A, Pratt GW. Functional arm bracing in supination. *J Bone Joint Surgery*.1975; 57:311-317.
9. Sarmiento A, Zagorski JB. Functional bracing of colles fractures, A prospective study of immobilization in supination vs pronation. *Clin Orthop* 1980; 146:175-183.
10. Fernandes DL, Fratures of the distal radius, Operative treatment. *Inst Course Lecture*. 1993; 42:73-88.
11. Wayne M, Weil MD, Thomas E. Treatment of distal radius fractures with intrafocal (kapandji) pinning and supplemental skeletal stabilization. *Hand Clinic*, 2005; 21:317-328.
12. Cassie Baum W. Colles Fractures, study of end results. *JMA* 1950; 143-148.
13. Nana AD, Joshi A. Plating of the distal radius. *JAM Acad Orthop Surg*. 2005; 13:159-171.
14. Stratan I, Dellature O. Improvement in pinning fixation for distal radius fracture. *Tech hand upper extremity surgery*. 2015; 19(3):101-107.
15. Clyburn T. Dynamic External Fixation for Communitied intra articular fracture of distal end Radius. *J Bone Joint Surg*.1987; 69:248-254.
16. Norikar U, Ota MD, Thoshiyasu Nakamura MD. Radiographic parameter analysis on modified Sauve Kapandji Procedure. *Journal of Wrist Surgery*. 2013; 2(1):19-26.
17. Goirand JGB. Distal Radius Fractures, Multiplanar Ligamentotaxis. *Hand Clinic* 1993; 9(4):577-585.
18. Randomized clinical trail of percutaneous Osteosynthesis and Minimally invasive Surgery. Evaluation of the distal end of radius fractures. *Rev Bras Orthop*. 2014; 49(3):218-226.
19. Percutaneous Cannulated Screw Fixation in the treatment of distal radius fractures. *Arch Orthop Trauma Surg*. 2012; 132:1335-1341.
20. Arel Gereeli, Metin Turkmen, Boris Kocaaglu. Comparative study of closed reduction percutaneous cannulated screw fixation and open reduction palmar locking plate fixation in the treatment of AO Type 2 distal radius fractures. *Arch Orthopaedic Trauma Surgery*. 2013; 134:121-129.

*All correspondences to: Dr. M.S. Patil, Professor, Department of Orthopaedic, Al-Ameen Medical College and Hospital, Athani Road, Vijayapur-586108 Karnataka, India. E-mail: mallangoudapatil721@yahoo.com